

# Variant Anatomy of Intracranial Part of Middle Meningeal Artery in a Kenyan Population

Julius Ogeng'o, Beda Olabu, Mary I Otiti, Beryl S. Ominde, Larry Mburu, Hemed Elbusaidy

Correspondence to Prof. Julius Ogeng'o Email: [jogengo@uonbi.ac.ke](mailto:jogengo@uonbi.ac.ke). Tel. +254720837592

## ABSTRACT

Anatomy of the intracranial part of middle meningeal artery is important during ligation or embolization in epidural haematomas, and in surgical approach to the middle cranial fossa. It shows population variations, but reports from African populations are scanty. This study aimed at describing the variant anatomy of intracranial part of middle meningeal artery in a black Kenyan population. One hundred and sixty middle meningeal arteries and grooves from 80 cadaveric cranial cavities of adult black Kenyans obtained from the Department of Human Anatomy, University of Nairobi Kenya were studied. Measurements taken included length of main trunk, horizontal distance from the branching point to a perpendicular line through midpoint of the zygomatic arch, and a horizontal line from the branching point to a perpendicular line through the tip of the tragus. The branching point of all intracranial divisions was anterior to the tragus and in majority of cases (84.9%) posterior to the mid-zygomatic line. The mean distance from the tip of tragus to the point of intracranial division was 30.6 mm, with 57.9% of the cases lying between 20 mm and 35 mm. The average vertical height of the artery from zygomatic point was 10.6 mm, with about two thirds (64.1%) between 3 mm and 22 mm. Majority (51.3%) of the intracranial trunks were between 5 mm and 13 mm long. There were 95.6% and 4.4% bifurcations and trifurcations respectively. The anterior division was deep to the pterion in 66.3%, posterior in 27.5% and anterior in 6.3% of cases. This study revealed that the termination point of the middle meningeal artery in the Kenyan population lies about 14 mm posterior to the mid zygomatic line and about 31 mm from a perpendicular line through the tip of the tragus. It displays variations in stem length, pattern of branching. Only two – thirds of anterior divisions lie deep to the pterion. Neurosurgeons should be aware of these variations during ligation or embolization of the artery and in enlarged middle cranial fossa approach.

**Key words:** Variations, Landmarks, Middle Meningeal artery, Intracranial, African

## INTRODUCTION

The middle meningeal artery (MMA), the largest of the meningeal arteries enters the cranial cavity through foramen spinosum medial to the

midpoint of the zygomatic bone and later divides into anterior (frontal) and posterior (parietal) branches to supply dura matter of middle

Received 28<sup>th</sup> May 2015. Edited 25<sup>th</sup> September 2015. Published online 27<sup>th</sup> September 2015. To cite: Ogeng'o J, Olabu B, Otiti MI, Ominde SB, Mburu L, Elbusaidy H. Variant Anatomy of Intracranial Part of Middle Meningeal Artery in a Kenyan Population. Anatomy Journal of Africa. 2015. Vol 4 (2): 571 – 577.

anterior and posterior cranial fossae (Snell, 2004; Sinnatamby 2006; Moore and Dalley, 2006). The artery is frequently torn in head injury to cause epidural haematoma (Gupta et al., 2008). Variant anatomy of intracranial course of middle meningeal artery is important during its ligation and embolization for epidural haematomas or to prevent expansion of chronic subdural haematoma (Manjunath and Thomas, 2000; Hirai et al., 2004; Da Silva et al., 2013),

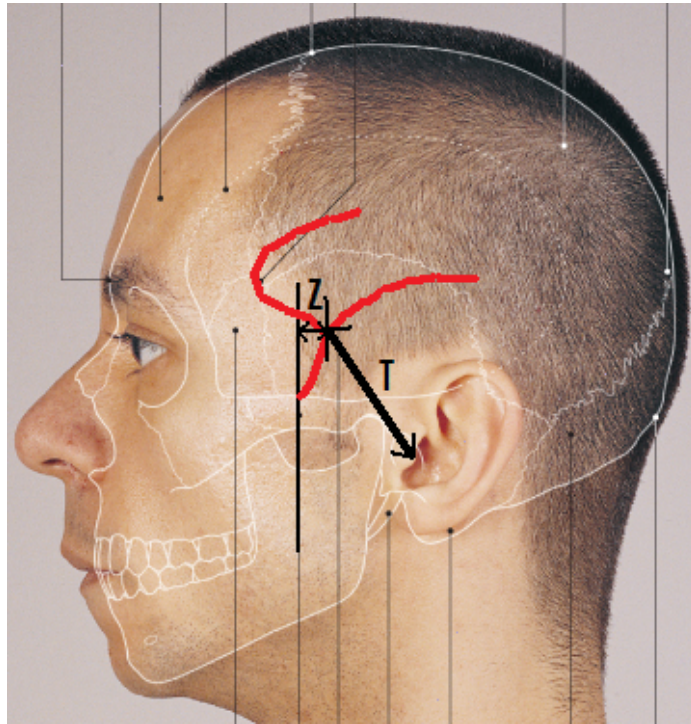
and in surgical approaches to the middle cranial fossa (Miguel et al., 1994; Tanriover et al., 2009). This anatomy displays population differences (Rothman, 1937; Manjunath and Thomas, 2000; Hirai et al., 2004). Data from African populations are, however, scarce. This study therefore aimed at describing the variant anatomy of the intracranial MMA in a Kenyan population.

## MATERIALS AND METHODS

The study was done on 160 middle meningeal arteries from 80 cadaveric cranial cavities of adult black Kenyans at the Department of Human Anatomy, University of Nairobi, Kenya. The skulls were opened using an oscillating saw by a circumferential incision through supraorbital ridge, the squamous temporal bone, superior nuchal line and external occipital protuberance. The calvarias were removed together with the underlying dura and the brains delivered whole. The grooves for the MMA were identified bilaterally and traced proximally to the foramen spinosum and distally to the terminal branches. The points of division were noted and superimposed on the external surface of the skulls after removing the soft tissues covering of the temporal fossae bilaterally. Measurements were taken using a flexitape and a cotton string applied to a digital Vanier caliper (accuracy 0.5 mm). Measurements taken were: (i) the length of the main trunk [L] from the foramen spinosum to the point of division; (ii) horizontal distance [Z] drawn from the point of division of the MMA

to the intercept with a line drawn vertically through the mid-point of the zygomatic arch [mid-zygomatic line]; and (iii) distance [T] from the point of division of the MMA to the tip of tragus (Figure 1).

Measurements Z and T were taken from external skull while L was taken from the middle cranial fossa. The intracranial trunk of the MMA was defined as the segment between foramen spinosum and the point of division. Terminal branching pattern was studied and recorded as either bifurcation or trifurcation. The relationship of the anterior branch with the pterion was determined and documented as medial, anterior or posterior. Micrographs of representative variations in course and branching pattern were taken using a high resolution digital camera. Data were analysed using statistical programme for social sciences version 16.0 for windows and are presented using macrographs and charts.



**Figure 1:** Surface landmarks of the lateral face and scalp showing how various measurements were taken. KEY: Z - horizontal distance from the point of division to the mid-zygomatic line; T - distance from point of division to the tip of tragus.

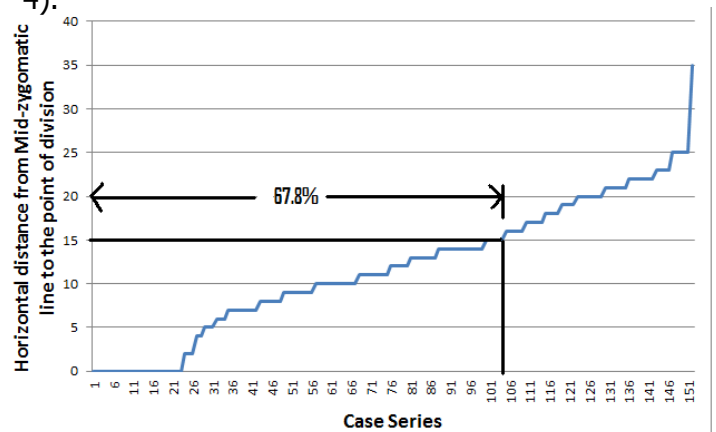
## RESULTS

The middle meningeal artery was bilaterally present and entered the cranial cavity through foramen spinosum in all cases.

### Measurements

The stem of MMA, hence the point of intracranial division, was found either posterior or directly opposite the mid-zygomatic line in 129 cases (84.9%) and 23 cases (15.1%) respectively. The mean distance (Z) from this line was 11.8 mm, with majority (103 cases; 67.8%) found within the first 15 mm (Figure 2). The mean distance (T) from the tip of tragus to the point of division of MMA was 30.6 mm, where 57.9% lay between 20 mm and 35 mm (Figure 3). The average vertical height of the intracranial middle meningeal artery from the point of division to the mid-zygomatic point was 10.6 mm, with about two thirds (64.1%) of the values lying between

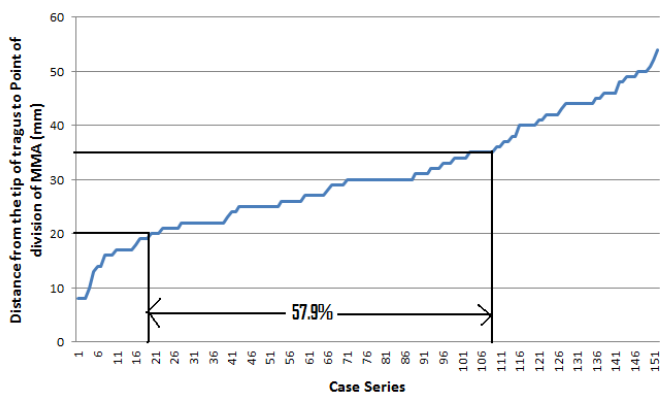
3 mm and 22 mm. The length of the main trunk was highly variable, ranging from 3 mm to 47 mm, with a mean of 15.8 mm, with 51.3% of the cases lying between 5 mm and 13 mm (Figure 4).



**Figure 2:** Horizontal distance from Mid-zygomatic line to point of Division of MMA

### Terminal Branching Pattern

Eight arteries (5%) had extracranial divisions hence appeared within the middle cranial fossa as two separate vessels. The rest of the arteries (95%; N=152) traversed the foramen spinosum as one single trunk which later divided intracranially. Out of these intracranial trunks, 11(7.2%) divided within the first 5 mm and were termed "short intracranial trunk" (Figure 5a). Twenty – six (17.1%) divided beyond the first 25 mm segment and were therefore termed "long intracranial trunk" (Figure 2b). Fifty - nine trunks (38.8%), however, terminated within the first 10 mm of their intracranial course. In 26

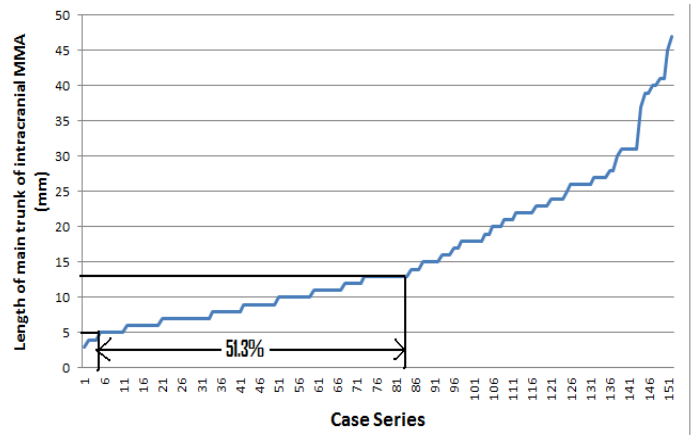


**Figure 3:** Length of the main trunk of intracranial MMA

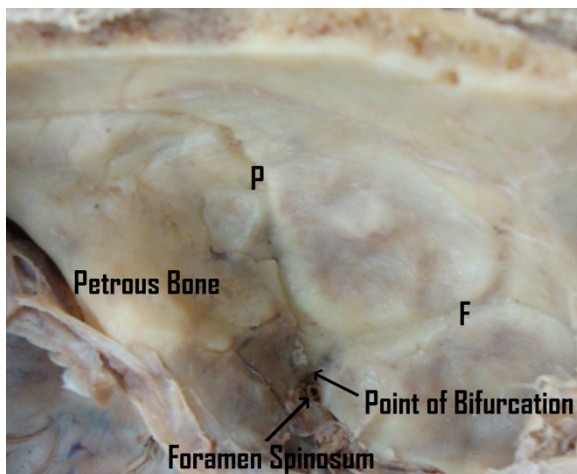
cases the main trunk ran through a bony canal within the cranial cavity before emerging. The artery trifurcated in 7 cases (4.4%) while 153 (95.6%), including the extracranial divisions, were bifurcations (Figure 5c).

### Relationship with pterion

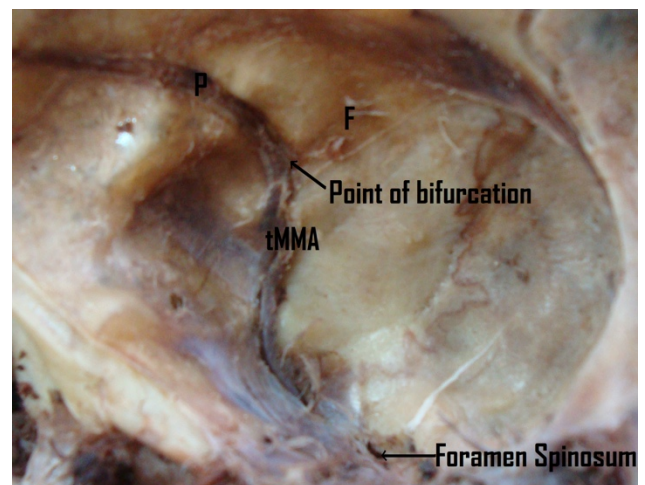
The most frequent location of the anterior division of MMA relative to the pterion was deep (106; 66.3%) followed by anterior (44; 27.5%) and posterior (10; 6.3%) [Fig 5D]. The mean distance from the pterion of those lying anterior was  $11.0 \pm 3.56$  mm while that of those lying posterior was  $12.41 \pm 5.76$ .



**Figure 4:** Length of the main trunk of intracranial MMA

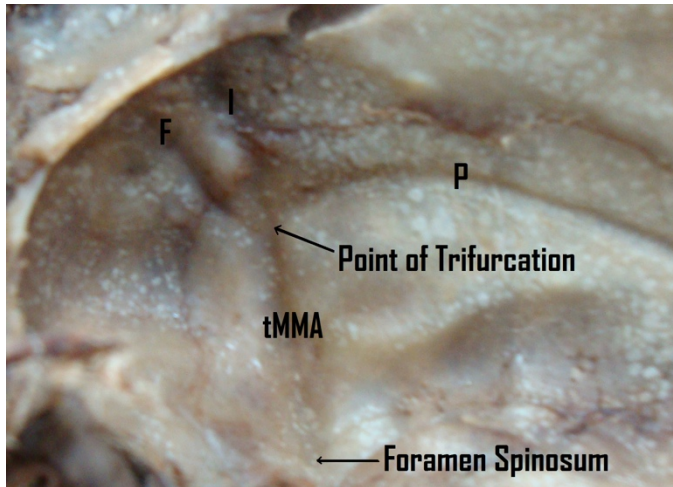


**Figure 5a:** Middle meningeal artery with a short intracranial length. KEY: P = Parietal Branch; F = Frontal Branch

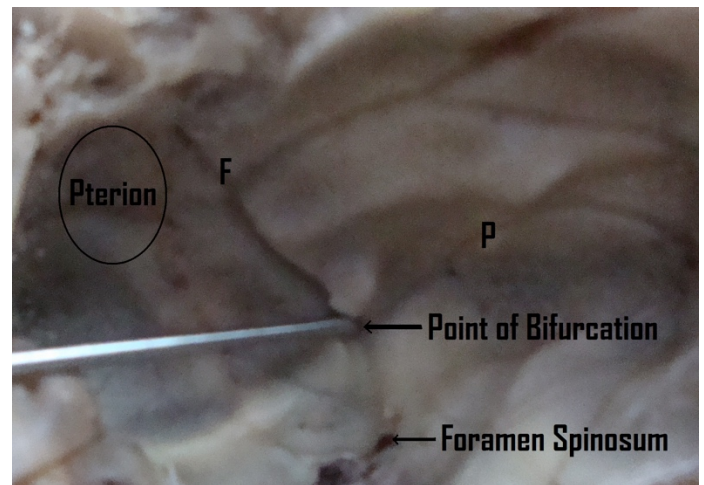


**Figure 5b:** Middle meningeal artery with a long intracranial length





**Figure 5C:** Middle meningeal artery with a long intracranial course and trifurcation F = Frontal Branch; I = Intermediate Branch; P = Parietal Branch; tMMA = Trunk of the middle meningeal artery



**Figure 5D:** Frontal Branch of MMA passing behind the Pterion. F = Frontal Branch; P = Parietal Branch

## DISCUSSION

### *Location in relation with the zygomatic arch*

The middle meningeal artery was bilaterally present in all the skulls studied, consistent with conventional text book descriptions (Standring et al., 2005). Observations of the current study reveal that the point of division lies approximately 12 mm posterior to the mid-zygomatic line, and about 30 mm from the tip of tragus. About two thirds of the arteries divided within the first one and a half centimeters from the mid-zygomatic line. These data are important in predicting the involvement of the artery in fractures of the side of the skull which may rupture it. The landmark is important for access of this artery during extradural haemorrhage. The burr hole is usually placed 25 to 40 mm above the midpoint of zygomatic arch (Snell, 2004). This is, in majority of our cases, a level higher than the point of division of the artery. The current study also reveals that the tip of the tragus may be a useful landmark for localizing the MMA.

### *The mean length of the artery*

The stem of the artery is defined as the portion of the artery between foramen spinosum and the point of terminal branching into frontal and parietal. It has been previously reported that the artery divides a short distance from foramen spinosum (Snell, 2004). Observations of the present study reveal that there are variable termination points with a mean trunkal length of about 16 mm. This is lower than 19.03 mm in Indians (Manjunath and Thomas, 2000) and 39.5 mm in Turkish (Ustun et al., 2006), but higher than 3.04 mm recently reported among Indians (Aggarwal et al., 2012). In the American population, the length of the stem varied from 2 to 55 mm (Plumer, 1896). These figures suggest that the length of MMA stem varies between populations and is concordant with reports that there is no constant distance at which the artery terminates (Manjunath and Thomas, 2000). Pertinent observations of the present study in support of these reports are that the artery divided extracranially in 5% of the cases. About

four out of ten MMA divide within the first 10 mm of its intracranial length, contrary to previous literature findings which report this to be about 1% (Plummer, 1896). These data are important to the neurosurgeon when ligating the artery in case of extradural haemorrhage due to its rupture, or in surgical approaches to/through the middle cranial fossa (Miguel et al., 1994; Tanriover et al., 2009, Aggarwal et al., 2012; Da Silva et al., 2013). Accordingly, prior evaluation of the artery may be necessary before ligation or embolization are attempted. MMA stem runs through bony canals in a significant number of cases. Bony canals have been described over both anterior and posterior branches with various incidences in many populations. These canals constitute sites of vascular compression and are major challenges during ligation (Manjunath and Thomas, 2000; Aggarwal et al., 2012).

#### *Termination pattern*

The MMA usually terminates by dividing into anterior (frontal) and posterior (parietal) branches (Sinnatamby 2000; Snell 2004; Moore and Dalley, 2006). In the current study, the artery trifurcated in 7(4.4%) cases. A third branch of MMA is consistent with literature reports (Klusovic et al., 1993). The true trifurcation observed however, appears to be at variance with the conventional classification where the middle branch arises from the frontal ramus (Type I); parietal ramus (type II) or from both frontal and parietal ramus (type III) [Giuffrida-Ruggeri, 1913; Adachi 1928]. The various types of branching described in literature as well as other variants were also observed in this study. These suggest that there are many

variations which may frustrate the neurosurgeon who relies entirely on textbook descriptions.

#### *Relation of anterior branch with pterion*

The pterion is the usual landmark for the anterior branch of MMA (Bozkir, 2004; Moore and Dalley, 2006; Ilknur et al., 2009). Observations of the current study reveal, however, that the anterior branch of MMA lies deep to the pterion in only 66.3% of cases, being posterior in 27.5% and anterior in 6.3%. Literature is silent on this variation, but it implies that pterional fractures may have a lower chance of rupturing the middle meningeal artery in this population. However, an unusually posterior branch may be more vulnerable to damage during extended middle cranial fossa approach (Miguel et al., 1994; Wigand, 1998; Tanriover et al., 2009)

In conclusion the termination point of the middle meningeal artery in the Kenyan population lies about 14 mm posterior to the mid zygomatic line and about 31 mm from a perpendicular line through the tip of the tragus. It displays variations in stem length and pattern of branching. Only about two thirds of anterior divisions lie deep to the pterion. Neurosurgeons should be aware of these variations during ligation or embolization of the artery and in enlarged middle cranial fossa approach.

**Acknowledgements:** We are grateful to Technical staff in the department of Human Anatomy for their support and Catherine Chinga for typing the manuscript.

**Source of Funding:** There was no external funding for this study

**Conflict of interest:** There is no conflict of interest

## REFERENCES

1. Adachi B. 1928. Das Arterian system der Japaner I, pp 93.
2. Aggarwal B, Gupta M, Kumar H. 2012. Bony canals along the course of middle meningeal artery in Dry skulls. NJCA 1: 19 – 23.
3. Bozkir M, Oguz O, Sanli S, Soames S. 2004. The pterion in Turkish male skulls. Surg Radiol Anat; 26: 220 – 224.
4. Da Silva TH, Ellwanger JH, Da Rosa HT, De Campos D. 2013. Origins of the middle meningeal artery and its probable embryological mechanism – A review. J Morphol Sci; 30: 67 – 72.
5. Ilknur A, Mustafa KI, Sinan B. 2009. Study of variation of pterion of Human skull from 13<sup>th</sup> to 20<sup>th</sup> century. Anatolia J Morphol; 27: 1291: 1298.
6. Hirai S, Ono J, Odaki M, Serizawa T, Nagano O. 2004. Embolization of the middle meningeal artery for refractory chronic subdural Hematoma. Usefulness for patients under Anticoagulant Therapy. Interv Neuroradiol; 10 (suppl 2): 101 – 104.
7. Guiffrida-Ruggeri V. 1913. Ueber Die endocranischen Furchen der Arteria meninges media beim menschem. Zeitschrift Fuer morphology and Anthropologie; 15: 401 – 413.
8. Gupta KD, Mahapatra K, Singh K. 2008. Bifrontal Hyper Acute Extradural Hematoma. Ind J Neurotrauma, 5: 44 – 45.
9. Klusovic D, Sikic E, Krmpotic – Nemanic J. 1993. Variations of the middle meningeal artery: Significance for surgery and practice. Clinical Anatomy; 6: 289 – 294.
10. Manjunath KY, Thomas IM. 2000. The course, relations and branching pattern of middle meningeal artery in South Indians. J Anat Soc India; 49: 133 – 138.
11. Miguel A, Yasar C, Essam S, Maged N, Mauro L, Abdel T, Mario S. 1994. Surgical Anatomy of the Extended Middle Cranial Fossa Approach. Skull Base Surgery; 4: 181–188.

12. Moore KL, Dalley II AF Eds. 2006. Middle meningeal artery. In clinically oriented Anatomy. Lippincott, Williams and Wilkins, 5<sup>th</sup> Edition; 916.
13. Plummer SC III. 1896. Research on the surgical Anatomy of middle meningeal artery. Ann Surg 1896; 23: 540 – 572.
14. Rothman D. 1937. The endocranial course the middle meningeal artery in American whites and American Negroes. Am J Phys Anthr; 22: 425 – 435.
15. Snell RS. 2004. Middle meningeal artery. IN clinical Anatomy. Lippincott, Williams and Wilkins, 7<sup>th</sup> Ed: pp 799.
16. Sinnatamby CS. 2000. Middle meningeal artery. IN Last's Anatomy – Regional and Applied. Elsevier, 11<sup>th</sup> edition pp 460.
17. Standring S, Ellis H, Healy JC, Johnson D. 2005. Middle Meningeal Artery. IN Gray's Anatomy 39 Ed. London Elsevier Churchill Livingstone pp 442 – 471.
18. Tanriover N, Sanus GZ, Ulu MO, Tanriverdi T, Akar Z, Rubino PA, Rhoton AL Jr. 2009. Middle fossa approach: microsurgical anatomy and surgical technique from the neurosurgical perspective. Surg Neurol; 71:586-596.
19. Ustun ME, Buyukmumcu M, Uiki CH, Guney O, Salbacak A. 2006. Transzygomatic subtemporal Approach for Middle Meningeal –to-p2 Segment of Posterior Cerebral Artery Bypass. An Anatomical and Technical study. Skull Base; 16: 39 – 43.
20. Wigand ME. 1998. Enlarged middle fossa approach to the cerebello pontine angle: Technique and indications. Rev Laryngol Otol Rhinol (Bord); 119: 159 – 162.